

DETECTING ORAL CANCER

A Guide for Health Care Professionals

INCIDENCE AND SURVIVAL

Oral or pharyngeal cancer will be diagnosed in an estimated 28,000 Americans this year, and will cause approximately 7,000 deaths. On average, 59 percent of those with the disease will survive more than five years.

THE IMPORTANCE OF EARLY DETECTION

Early Detection Saves Lives

With early detection and timely treatment, deaths from oral cancer could be dramatically reduced.

The five-year survival rate for those with localized disease at diagnosis is 81 percent compared with only 30 percent for those whose cancer has spread to other parts of the body.

Early detection of oral cancer is often possible. Tissue changes in the mouth that might signal the beginnings of cancer often can be seen and felt easily.

WARNING SIGNS

Lesions that might signal oral cancer

Two lesions that could be precursors to cancer are leukoplakia (white lesions) and erythroplakia (red lesions). Although less common than leukoplakia, erythroplakia and lesions with erythroplakic components have a much greater potential for becoming cancerous. Any white or red lesion that does not resolve itself in two weeks should be reevaluated and considered for biopsy to obtain a definitive diagnosis.

Other possible signs/symptoms of oral cancer

Possible signs/symptoms of oral cancer that your patients may report: a lump or thickening in the oral soft tissues, soreness or a feeling that something is caught in the throat, difficulty chewing or swallowing, ear pain, difficulty moving the jaw or tongue, hoarseness, numbness of the tongue or other areas of the mouth, or swelling of the jaw that causes dentures to fit poorly or become uncomfortable.

If the above problems persist for more than two weeks, a thorough clinical examination and laboratory tests, as necessary, should be performed to obtain a definitive diagnosis. If a diagnosis cannot be obtained, referral to the appropriate specialist is indicated.

RISK FACTORS

Tobacco/Alcohol Use

Tobacco and excessive alcohol use increase the risk of oral cancer. Using both tobacco and alcohol poses a much greater risk than using either substance alone.

Sunlight

Exposure to sunlight is a risk factor for lip cancer.

Age

Oral cancer is typically a disease of older people usually because of their longer exposure to risk factors. Incidence of oral cancer rises steadily with age, reaching a peak in persons aged 65-74. For African Americans, incidence peaks about 10 years earlier.

Gender

Oral cancer strikes men twice as often as it does women.

WHAT YOU CAN DO

A thorough head and neck examination should be a routine part of each patient's dental visit. Clinicians should be particularly vigilant in checking those who use tobacco or excessive amounts of alcohol.

- **EXAMINE** your patients using the head and neck examination described here
- **TAKE A HISTORY** of their alcohol and tobacco use
- **INFORM** your patients of the association between tobacco use, alcohol use, and oral cancer
- **FOLLOW-UP** to make sure a definitive diagnosis is obtained on any possible signs/symptoms of oral cancer

THE EXAM

This exam is abstracted from the standardized oral examination method recommended by the World Health Organization. The method is consistent with those followed by the Centers for Disease Control and Prevention and the National Institutes of Health. It requires adequate lighting, a dental mouth mirror, two 2 x 2 gauze squares, and gloves; it should take no longer than 5 minutes.

THE EXAMINATION

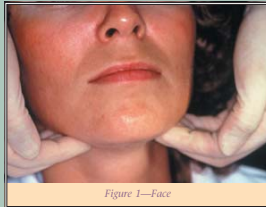

Figure 1—Face

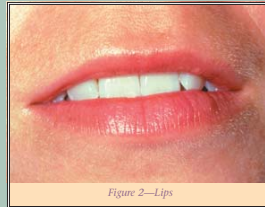


Figure 2—Lips

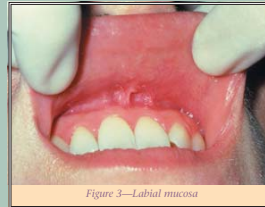

Figure 3—Labial mucosa

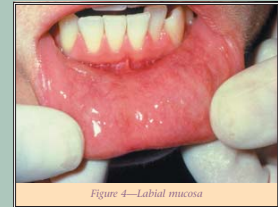

Figure 4—Labial mucosa

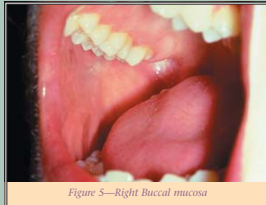

Figure 5—Right Buccal mucosa

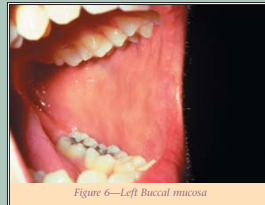

Figure 6—Left Buccal mucosa

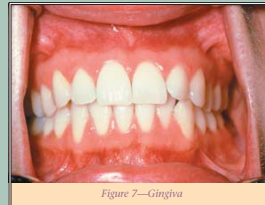

Figure 7—Gingiva

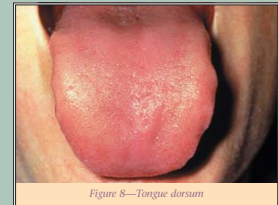

Figure 8—Tongue dorsum

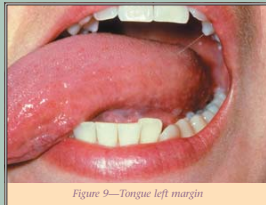

Figure 9—Tongue left margin

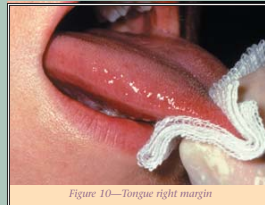

Figure 10—Tongue right margin

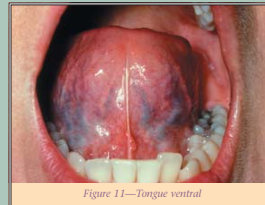

Figure 11—Tongue ventral

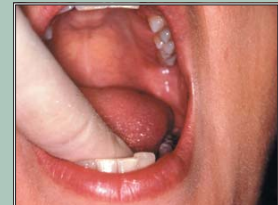

Figure 12—Floor

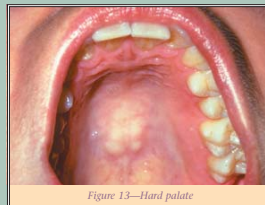

Figure 13—Hard palate

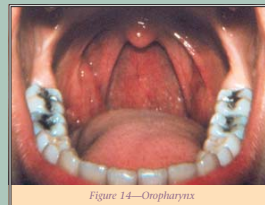


Figure 14—Oropharynx

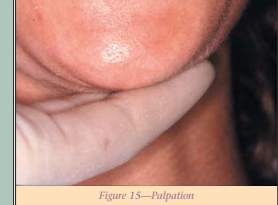

Figure 15—Palpation

The examination is conducted with the patient seated. Any intraoral prostheses are removed before starting. The extraoral and perioral tissues are examined first, followed by the intraoral tissues.

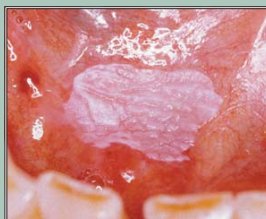- The Extraoral Examination
 - ◆ FACE: (Figure 1)
- Perioral and Intraoral Soft Tissue Examination

- ◆ LIPS: (Figure 2)
- ◆ LABIAL MUCOSA: (Figures 3 and 4)
- ◆ BUCCAL MUCOSA: (Figures 5 and 6)
- ◆ GINGIVA: (Figure 7)

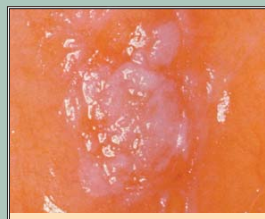- ◆ TONGUE: (Figures 8-11)
- ◆ FLOOR: (Figure 12)
- ◆ PALATE: (Figures 13-15)

ORAL LESIONS

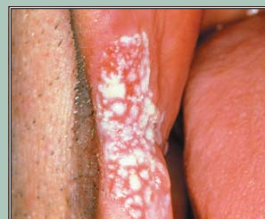Suspicious for Oral Cancer



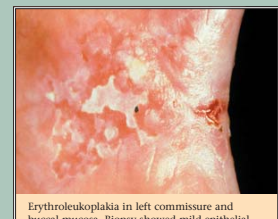
Homogenous leukoplakia in the floor of the mouth in a smoker. Biopsy showed hyperkeratosis.



Clinically, a leukoplakia on left buccal mucosa. However, the biopsy showed early squamous cell carcinoma. The lesion is suspicious because of the presence of nodules.



Nodular leukoplakia in right commissure. Biopsy showed severe epithelial dysplasia.



Erythroleukoplakia in left commissure and buccal mucosa. Biopsy showed mild epithelial dysplasia and presence of candida infection. A 2-3 week course of anti-fungal treatment may turn this type of lesion into a homogenous leukoplakia.